

# Effectiveness of Acyclovir on Meniere's Syndrome

## III Observation of Clinical Symptoms in 301 Cases

Mitsuo SHICHINOHE, M. D., Ph. D.

*Director, Shichinohe Clinic, 9-Jo, 3-Chome, Taihei, Kita-ku, Sapporo 002-8009, Japan*

札幌医学雑誌 第68巻 4-6号 別刷

平成11年12月

Reprinted from The Sapporo Medical Journal Vol. 68, No. 4-6, December, 1999

# Effectiveness of Acyclovir on Meniere's Syndrome III Observation of Clinical Symptoms in 301 Cases

Mitsuo SHICHINOHE, M. D., Ph. D.

*Director, Shichinohe Clinic, 9-Jo, 3-Chome, Taihei, Kita-ku, Sapporo 002-8009, Japan*

**ABSTRACT** Despite a variety of proposed causes, the real etiology of Meniere's disease (MD) is still unknown. Since no effective treatment has been established yet, the patients with this disease usually suffer from the uncomfortable symptoms for a long period and repeated recurrences. The symptoms and pathologic changes reported to date, led the author to the idea that the majority of MD is caused by viral infection to vestibulocochlear area, probably herpesvirus infection. The author attempted to administer acyclovir (ACV) to patients with MD and obtained a dramatic therapeutic effect. Between October 1990 and October 1997, 301 patients were administered ACV with the dose of 2,000 mg/day for the average period of two weeks. The effectiveness was evaluated by objective and subjective symptoms of patients with MD under a definite criteria comparing features between pre- and after-ACV administration referring to AAO-HNS criteria. Special attention was paid to the patients followed more than three years after the treatment (about 150 cases) for the detailed evaluation of effectiveness.

Out of 250 evaluable cases 89 cases showed "marked effect" and 116 cases were "effective", indicating total 205 effective cases (82.0%). There were 24 unclear cases (9.6%). Only 21 cases (8.4%) showed "no effect". No side effect was observed in this series of the study.

(Received July 19, 1999 and accepted October 25, 1999)

**Key words:** Meniere's disease, Acyclovir, Vestibul cochlear nerve, Herpesviridae infection

## 1 Introduction

The definite cause of MD is not clear yet but endolymphatic hydrops has been recognized. Several causes have been suggested such as allergy, disorder of the autonomic nervous system and stress. Viral infection has also been implicated<sup>1-3)</sup>, however, no trial of anti-viral treatments has been reported to date except the author's two papers<sup>4,5)</sup>.

More than ten years, the author has suspected from clinical experiences that MD would be a viral infectious disease. In many cases patients recover from the disease after the acute stadium but they encounter repeated exacerbation. This process resembles that of a latent infection and recurrence in herpes labialis, herpetic gingivostomatitis. As for Bell's palsy and Ramsey-Hunt syndrome, ACV is commonly used, because they are considered as viral infectious diseases. Before the use of antiviral medicine for Bell's palsy, it took approximately three to six months to recover from the disease and in some cases only partial recovery was seen, which made it difficult to predict the prognosis at the early stage of the disease. Many doctors have observed the similarity in the process of MD and Bell's palsy.

If, in fact, MD is a viral infectious disease, and judged from how many the cases are commonly found, it is quite possible to surmise that the cause of the disease to be some common virus, such as herpesvirus. Based on this idea, the author has administered ACV to patients with MD and obtained a dramatic effectiveness.

The author reported these results previously<sup>1,2)</sup> but with a small number of cases. In this report, a sufficient number of follow-up cases were investigated and the cause of MD is discussed, narrowing the focus into the effectiveness of ACV on clinical symptoms.

## 2 Materials and Methods

### 2.1 Patients

The cases studied include 301 patients who visited Shichinohe clinic, of which the author is the director, between the period of October 1990 and October 1997, with symptoms of vertigo, ear tingling (tinnitus aurium) and impaired hearing. Out of those 301 cases, 10 were diagnosed in Shichinohe clinic. 291 cases were diagnosed mainly by specialists of otolaryngology. Among them 135 cases were diagnosed as MD, 99 as Meniere's syndrome, 52 as vestibular dysfunction and 15 as others (Table 1). Ninety-six were male ranging from 13 to 81 yrs of age and 205 were female ranging from 19 to 84 yrs of age. Duration of the disease (the period between the first attack and the administration of ACV) varied from 1-20 days for the patients with first attack to 1-30 years for the chronic patients who had repeated attacks, exacerbation, recurrences and partial remissions.

### 2.2 Evaluation of effectiveness of treatment

The process of the disease was recorded in detail in the records of the patients. The subjective symptoms were told and described by the patients themselves and family members and also recorded. Special attention was paid to frequency and severity of spells of vertigo, intensity of tinnitus described by patients referring to AAO-HNS criteria. Evaluation of hearing was made mainly by subjective description of patients. Some of them were sent to otolaryngologists and received audiogram tests. Most of the patients were also observed and evaluated clinical effectiveness of the treatment by other doctors.

Effectiveness of the treatment was evaluated comparing improvement of symptoms (frequency and severity of spells of vertigo, intensity of tinnitus and hearing disorder) by the previous treatments with that by ACV treatment. The results were described as follows. Marked effect: vertigo and tinnitus completely disappeared, Effective: vertigo disappeared, tinnitus and hearing improved, Unclear effect: vertigo and tinnitus improved, hearing not improved, No effect: vertigo, tinnitus and hearing not improved, Not evaluable: follow-up study could not be carried out, because the patients did not contact doctors after treatment.

In some cases, blood samples were obtained from the patients in spells of illness and convalescence. Antibody titers to herpes simplex virus (HSV) and varicella zoster (VZV) were examined by indirect immunofluorescence. Peripheral blood mononuclear cells (PBMCs) were tested for presence of genomic DNA of HSV, VZV, and cytomegalovirus (CMV) by nested polymerase chain reaction (PCR)<sup>3)</sup>.

## 3 Results

### 3.1 Results of ACV treatment

Out of 301 cases treated with ACV, 250 cases (83.1%) were evaluable having contact with doctors after the treatment. Follow-up study

Table 1 Clinical Diagnosis of Cases Studies

Diagnosis	Male	Female	Total
Meniere's Disease <sup>*1</sup>	38	97	135
Meniere's Syndrome <sup>**</sup>	35	64	99
Vestibular Dysfunction <sup>**</sup>	19	33	52
others <sup>**</sup>	4	11	15
Total	96	205	301

<sup>\*1</sup> as diagnosed by otolaryngologists from clinical criteria

<sup>\*\*</sup> as diagnosed by otolaryngologists, including cases which showed symptoms of Meniere's disease but could not completely exclude other basic diseases

<sup>\*\*</sup> as diagnosed by otolaryngologists

<sup>\*\*</sup> others include dysfunction of autonomous nervous system, side effect of gentamycin, cerebrovascular disorder and diseases of unknown causes

could not be made in 51 cases (16.9%), since the patients did not contact the doctors after the treatment. Eighty-nine cases showed "marked effect" and 116 cases were "effective", indicating total 205 effective cases among 250 evaluable cases (205/250, 82.0%). Only 21 cases (21/250, 8.4%) showed "no effect" (Table 2). No side effect was observed in this series of the study. Almost the same results (more than 80% effective) were obtained in patients diagnosed as MD (94/114, 82.5%) and Meniere's syndrome (68/80, 85.0%) and vestibular dysfunction (41/46, 89.1%), however, 70% (7/10) of no effect case was observed in patients diagnosed as other diseases.

### 3.2 Relationship between effectiveness of ACV and duration of disease

There was a significant relationship between effectiveness of ACV therapy on MD and duration of the disease as shown in Fig. 1. The ACV treatment was more effective to patients with shorter duration of disease from onset than patients with longer duration. In other words, the more longer duration the cases had, the more number of ineffective cases increased. Cases with duration of less than 6 months showed a marked effect resulting 43 cases (95.6%) of "marked effect" plus "effective" out of 45 cases, whereas cases with duration of more than 10 years revealed the increase of ineffective cases showing 19 cases (28.3%) of "unclear effect" plus "no effect" out of 67 cases. It was surprising that, even in cases with duration of 6M-10Y, more than 80% of "effective" plus "marked effect" were observed.

### 3.3 Clinical features and recurrences after ACV treatment

It was quite impressive that ACV was

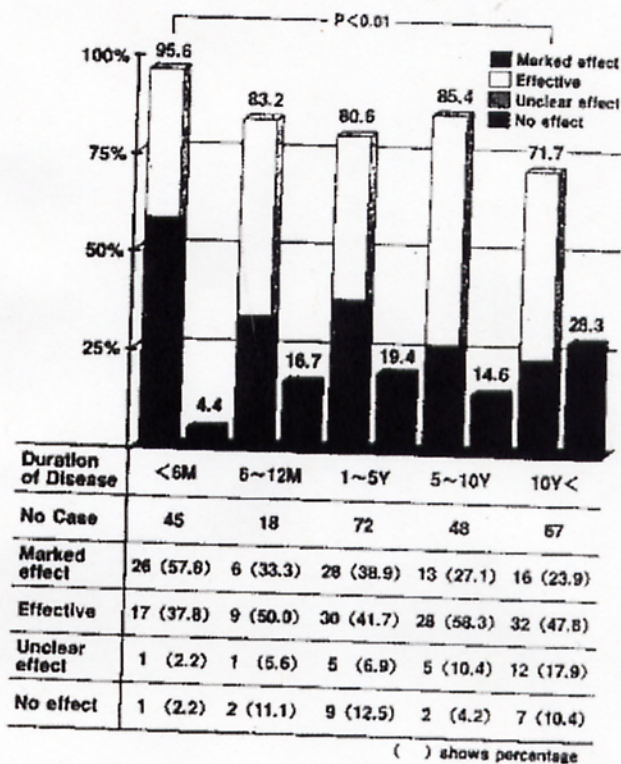


Fig. 1 Effectiveness of Acyclovir and Duration of Disease.

Table 2 Effectiveness\* of ACV on Meniere's Syndrome

Clinical Diagnosis of Cases Studied	Marked Effect	Effective	Unclear Effect	No Effect	Not Evaluatable	Total
Meniere's Disease	41	53	12	8	21	135
Meniere's Syndrome	26	42	7	5	18	98
Vestibular Dysfunction	21	20	4	1	7	53
Others	1	1	1	7	5	15
Total	89	116	24	21	51	301

\* Criteria of Effectiveness

marked effect: vertigo and ear tingling completely disappeared

effective: vertigo disappeared, ear tingling and hearing improved

Unclear effect: vertigo improved, ear tingling and hearing not improved

No effect: vertigo, ear tingling and hearing not improved

Not evaluatable: Follow-up study could not be carried out, since the patients did not contact doctors after administration of ACV



extremely effective to vertigo. In "effective" cases, vertigo disappeared usually, but tinnitus was not completely improved. Most of the patients treated revealed improvement of clinical symptoms 3-7 days after the administration of ACV. After 10 to 14 days, the patients rapidly recovered and clinical symptoms disappeared. Recurrence of the disease, which the author confirmed, occurred in 39 cases out of 301 cases (13.0%) but they usually could be cured by ACV treatment with lower doses (less than half doses of the first administration of ACV) within shorter period (less than half time of the first ACV treatment).

### 3-4 Detection of HSV and antibody to HSV in patients with MD

Until now, there have been no significant differences in the mean antibody titers to HSV-1 or VZV between the patients with MD and patients before and after ACV treatment (unpublished data). In some cases, HSV-1 or VZV DNA were detected in MD patients by PCR, however, significant correlations of virus detection and clinical features have not been demonstrated yet. Details of serological and virological investigation will be described in the separated paper<sup>21</sup>. Further investigations are being underway.

### 3-5 Demonstration of representative cases

Followings are the 2 typical representative cases of the treatment of MD with ACV.

Case 1 H. M. 68-year-old, female

This patient was diagnosed as MD in 1980 and was treated by specialists for 15 years. She said she had attacks of "dizziness" 4 to 5 times a year. Hearing disturbance and tinnitus were not intensive. She had been treated by specialists of otolaryngology at a university hospital in Tokyo and a general hospital in Sapporo. She said it usually took about one month for the traditional treatment with Meiron and Isobide to reduce her symptoms. She was told to visit a neuro-internal medicine and visited a neurologist and a psycho-analyst. Neurological test and psychiatric test revealed no abnormality other than symptoms of MD.

When she came to the author's clinic on Feb. 3, 1994, she had completely lost her confidence, wondering if she was going insane. She started to take 1,000 mg/day ACV on Feb. 3. On Feb. 5, she came to the author's clinic again and said the "dizziness" had disappeared. She told that the effect was a new experience. She took ACV for 9 days and the treatment was complete. Although the dizziness recurred 4 months and 13 months later, the same treatment could repress the symptoms. For the past 2 years, she has not had any episodes of "dizziness".

According to AAO-HNS criteria, improvement with ACV therapy on this patient was calculated as numeric value 20 (substantial control of definitive spells). Hearing and tinnitus were also much improved from her expression.

Case 2 N. K. 17-year-old female, Highschool student

In January, 1995, she experienced sudden rotary vertigo as she was sitting in a class. She rested in her nurse's room for about an hour, and the dizziness naturally disappeared. The same symptom recurred twice the following week. She went to the otolaryngology department of a university hospital and received a special examination. There, she was told that balance function of her left ear was a little weakened, but they gave her no particular treatment. She had tinnitus occasionally, but this was not very disturbing to her. However, for about 5 months before she visited the author's clinic, she was constantly having "dizziness" in everyday life, saying the floor was shaking like it would earthquake. She stopped going to school by bicycle because she felt it was dangerous. When the dizziness was serious, she often could not go to school. She was diagnosed as MD by the author and was given 2,000 mg/day of ACV for 2 weeks from May 8, 1995. Vertigo and tinnitus disappeared. She could go to school by bicycle again, since then, through April of 1997, there has been no relapse.

According to AAO-HNS criteria, improvement with ACV therapy on this patient was calculated as numeric value 0 (complete control of definitive spells). No complaints were expressed about hearing after the therapy.

## 4 Discussion

### 4.1 Diagnosis of MD

For general physician, it is almost impossible to satisfy all the requirements of tests that the Japanese Ministry of Health and Welfare proposed for diagnosis of MD. In many cases, if the attacks were relatively mild, the patients visit general physicians, but in case of severe attacks, patients are usually sent to neurosurgeons by ambulances. In most cases, patients enter partial remission in about 3 days, however, they require 1 to 3 months to get back to a normal life cycle. When whirling sensation, tinnitus, hearing disorder attack the patient repeatedly, he would often be suggested to visit otolaryngologists.

In this study, the author accepted the test results and diagnoses of specialists of otolaryngology, neurology and neurosurgery, where the patients experienced such tests as CT, MRI, intelligence tests, psychoanalyses, etc., except 10 cases which he diagnosed according to the typical clinical symptoms of the patients.

### 4.2 Clinical evaluation of effectiveness of the treatment.

The randomized well controlled study should be required to prove the effectiveness of the new trial of treatment for a disease. The author first intended to make the randomized controlled study to evaluate the effectiveness of the ACV therapy on Meniere's syndrome. However, he could not carry out a double-blind controlled study, since the patients knew the effectiveness of ACV and wished to be treated with ACV. A guideline for evaluating improvement of dizziness, hearing and equilibrium in MD (AAO-HNS criteria) has been reported<sup>9)</sup>, however, assessment of hearing could not be always made for all of the patients. In this report, the author used his own criteria of effectiveness, as mentioned above, including both subjective and objective evaluations, and this seemed to work well. If the author would have used AAO-HNS criteria, about 90% of cases of "marked effect" and "effective" of the author's criteria would have been 0 in numeric value (complete control of definitive spells), since only about 10% cases showed recurrence within 24 months after ACV treatment. The author is trying to re-evaluate the records of his patients according to AAO-HNS criteria.

### 4.3 Treatment with ACV

There are several papers suspecting viral infection is the cause of MD<sup>6-8)</sup>. As for the treatment of MD using anti-viral remedy, there have been no reports except the author's previous two papers<sup>1,2)</sup>. Therefore, the dosage and duration of administration of ACV had to be determined in accordance with the treatment against herpes simplex and genital herpes without any certain ground in treatment of MD. To date, there is no reason to consider the dosage and duration of ACV administration in this report is not appropriate.

### 4.4 About recurrences

Out of 301 cases 39 had recurrences. All of the patients with recurrent disease wanted to be treated with ACV. If MD would be caused by herpes virus, it should be natural to presume recurrence occur in the disease. Generally speaking, in the case of Herpes simplex, it is known that re-treatment with ACV will make the interval of recurrences longer or will prevent recurrences for several years. It is confirmed that the same is true in ACV-therapy of MD by current follow-up study of many cases.

### 4.5 HSV and VZV as causative agents of MD

The dramatic effects of the treatment with ACV for MD strongly suggested that MD is caused by

the viral infection in vestibulocochlear nerve. Judging from the pharmacological effect of ACV, herpes simplex viruses (HSV) and varicella zoster virus (VZV) are suggested to be causative agents. Furuta, *et al.*<sup>6)</sup> detected HSV-1 in 6 out of 10 cases by PCR of vestibular ganglia of autopsy materials. Kumagami<sup>7)</sup> showed that HSV antigen and DNA were observed in 9 out of 14 cases in the endolymphatic sac of autopsy materials. In their studies, the relationships between HSV-1 and MD were not shown, however, they indicated the possibility of the existence of latent infection of HSV-1 in the vestibular nerve and lymphatic sacs.

#### 4.6 Pathogenesis of MD

Among investigation of causative agents of MD, William, *et al.*<sup>6)</sup> described a significant elevation of both humoral and cellular immune responses against viral antigens of HSV-1 and VZV, rubella and cytomegalovirus in 25 patients with chronic MD. Welling, *et al.*<sup>7)</sup> detected HSV DNA in 2 of 22 extracts from endolymphatic sacs of MD patients. Whereas Arnold *et al.*<sup>8)</sup> reported the presence of a higher level of specific anti-HSV IgG in the perilymph of patients with MD. The author and co-workers<sup>3)</sup> detected herpes virus DNA in peripheral blood mononuclear cells of some MD patients and are still continuing the investigation to demonstrate with virus infection in MD cases and the correlation of the infection to clinical symptoms. These studies strongly suggest that the considerable number of MD cases are caused by the infection of HSV and/or VZV in vestibulocochlear area of the MD patients and give the ground to use anti-viral drugs such as ACV for the treatment of MD.

#### Acknowledgement

The author would like to express his gratitude to Dr. Mitsunori Ueno, director of Ueno Otolaryngology clinic, for giving access to his data including audiograms. He would also like to thank Prof. Emeritus Kokichi Kikuchi, Sapporo Medical University School of Medicine, for his thoughtful and helpful advice.

#### References

1. Shichinohe M. Effectiveness of ACV for Meniere's disease. *Igaku no Ayumi (J Clin Exp Med)* 1994, 169: 796-797 (In Japanese).
2. Shichinohe M. Effectiveness of ACV for Meniere's disease II. Report of 10 cases. *Shindan to Chiryō (Diagnosis and Treatment)* 1994, 82: 1860-1864 (In Japanese).
3. Takahashi K, Aono T, Shichinohe M, Tamura M, Shigeta S. Herpes virus DNA in peripheral blood mononuclear cells of some patients with Meniere's disease (personal communication).
4. Furuta Y, Takasu T, Fukuda S, Inuyama Y, Sato KC, Nagashima K. Latent Herpes simplex virus type I in human vestibular ganglia. *Acta Otolaryngol (Stockh)* 1993, Suppl 503: 85-89.
5. Kumagami H. Detection of viral antigen in the endolymphatic sac. *Eur Arch Otolaryngol* 1996, 253: 264-267.
6. William LL, Lowery HW, Shannon BT. Evidence of persistent viral infection in Meniere's disease. *Arch Otolaryngol Head Neck Surg* 1987, 113: 392-400.
7. Welling DE, Daniels RL, Brainard J, Western LM, Prior TW. Detection of viral DNA in endolymphatic sac tissue from Meniere's disease patients. *Am J Otolaryngol* 1994, 15: 639-643.
8. Arnold W, Niedermyer HP. Herpes simplex virus antibodies in the perilymph of patients with Meniere's disease. *Arch Otolaryngol Head Neck Surg* 1997, 123: 53-56.
9. Committee on Hearing and Equilibrium. Guidelines for reporting treatment results in Meniere's disease. *Otolaryngol Head Neck Surg* 1985, 93: 579-581.

別刷り請求先

(〒002) 札幌市北区太平9条3丁目

札幌市北のへ内科 七戸満雄